

EX VIVO AND IN VIVO ORAL CANCER DIAGNOSIS USING BACKWARD-COLLECTED THIRD HARMONIC GENERATION BIOPSY

Shih-Peng Tai¹, Dar-Bin Shieh², Wen-Jeng Lee³, Che-Hang Yu¹, Ping-Ching Wu², Yana Wu², and Chi-Kuang Sun¹

- 1. Department of Electrical Engineering and Graduate Institute of Electro-Optical Engineering, National Taiwan University, Taipei, TAIWAN
E-mail : sun@cc.ee.ntu.edu.tw**
- 2. Institute of Oral Medicine, National Cheng Kung University, Tainan, TAIWAN**
- 3. Department of Electrical Engineering, National Taiwan University and
Department of Medical Imaging, National Taiwan University Hospital, Taipei,
TAIWAN**

KEY WORDS: Third harmonics generation microscopy, Cancer diagnosis

Recently, we demonstrated the first reflection type harmonics optical biopsy (HOB) of fixed human skin specimens using a femtosecond Cr:forsterite laser centered at 1230 nm [1]. In our previous studies, without complex physical biopsy procedures and with combined backward propagating second harmonics generation (B-SHG) and third harmonics generation (B-THG), the structures from epidermis into dermis could be clearly identified with a high spatial resolution in all three dimensions. The penetration depth of HOB in fixed human skins is more than 400 μ m. Therefore, it is ideal for intrinsic optical sectioning in optical biopsy applications. To further demonstrate the HOB is ideal for clinical noninvasive disease diagnosis especially for cancer, both normal and cancerous oral tissues of hamsters were imaged with HOB based on backward propagation optical harmonics signals in this preliminary animal test. Figure 1 illustrates a typical *ex vivo* sectioning of (a) normal versus (b) cancerous hamster oral tissues (thickness 2-3mm). From B-THG images, a significantly enhancement of intercellular junctions was evident in normal oral epithelia while the intercellular junction B-THG is blurred in the cancer cells. On the other hand, strongly enhanced cytoplasmic and nucleoli B-THG signals were evident in the cancer cells. Such different B-THG images between normal and cancerous tissues may be due to derangement of the cytoskeleton organization, alterations in cell-cell adhesion, and nuclear activity known to take place during carcinogenesis progression. Our *ex vivo* studies indicated that HOB based on backward propagation optical harmonics signal with a high spatial resolution is ideal for oral cancer diagnosis. Following the *ex vivo* studies, we then performed the *in vivo* imaging of normal oral keratinocytes and oral cancer lesions in live hamsters. Hamster oral cancer model was established by orthotopic implantation of a hamster oral cell line (HCDB1). The hamster was used for this study two weeks after cancer lesions induction. Figure 1(c) shows an example *in vivo in situ* B-THG image taken in the oral cavity of live hamsters. We can *noninvasively* observe detailed sub-cellular structures from mucosa into sub-mucosa with a high spatial resolution without any exogenous markers. Detailed discussion on the *in vivo* noninvasively biopsy results of healthy and cancerous hamsters will be presented in the conference.

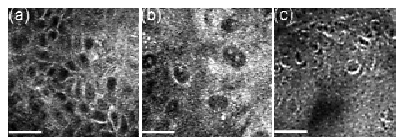


Fig. 1 Horizontally sectioned B-THG images of *ex vivo* hamster oral normal (a), *ex vivo* cancerous (b) and *in vivo* oral normal (c) tissues at different depths. Scale bar: 20 μ m.

[1] S.-P. Tai, et al., "Optical biopsy of fixed human skin with backward-collected optical harmonics signals," *Optics Express* **13**, 8231 (2005)